

Results from an Observational Trial: Digital Epiluminescence Microscopy Follow-Up of Atypical Nevi Increases the Sensitivity and the Chance of Success of Conventional Dermoscopy in Detecting Melanoma

Holger A. Haenssle¹, Ullrich Krueger¹, Claudia Vente¹, Kai-Martin Thoms¹, Hans P. Bertsch¹, Markus Zutt¹, Albert Rosenberger², Christine Neumann¹ and Steffen Emmert¹

We analyzed the value of digital epiluminescence microscopy (DELM) for the long-term follow-up of atypical nevi. Patients ($n=530$) were prospectively categorized into defined melanoma risk groups and followed by clinical and epiluminescence microscopy (ELM) examinations. Atypical nevi ($n=7001$) were additionally followed by DELM. During follow-up (median 32.2 months), we detected 53 melanomas among 637 excised lesions (8.3% overall chance of success). The chance of success for melanoma detection among lesions suspicious by ELM criteria was increased to 17% when additional DELM-documented changes were present. Moreover, 18 of the 53 melanomas were exclusively identified by DELM-documented changes, indicating that DELM increased the sensitivity of the ELM analysis by identifying additional melanomas. However, for lesions exclusively excised due to DELM changes, the chance of success was lower than for ELM (5.2 vs 11.8%). Excisions due to mere DELM changes detected 66.7% of melanomas in familial atypical mole and multiple melanoma (FAMMM) and 32.5% of melanomas in atypical mole syndrome (AMS) patients. We conclude that DELM is a valuable tool for the long-term follow-up of atypical nevi, especially in the high-risk groups of FAMMM and AMS patients. Randomized controlled trials are needed to validate the data from this clinical trial.

Journal of Investigative Dermatology advance online publication, 2 March 2006; doi:10.1038/sj.jid.5700119

INTRODUCTION

The most effective approach to improve the prognosis of cutaneous melanoma is early recognition and surgical excision of thin lesions (Breslow, 1980). In addition to a basic naked-eye examination, epiluminescence microscopy (ELM) has been shown to improve the diagnostic accuracy for early melanoma detection (Ascierto *et al.*, 2000). However, ELM does not reach 100% diagnostic accuracy mostly due to a lack of distinct dermoscopic features either in far-progressed featureless melanomas (Carli *et al.*, 2002) or in very early melanomas (Kittler *et al.*, 2000). It might therefore be necessary to base the management of atypical pigmented skin

lesions on additional information, for example deriving from the longitudinal observation of dynamic changes. Until now, only few reports on digital epiluminescence microscopy (DELM) follow-up of melanocytic skin lesions have been published with heterogeneous results (Braun *et al.*, 1998; Kittler *et al.*, 2000; Kittler and Binder, 2001; Menzies *et al.*, 2001; Schiffner *et al.*, 2003; Haenssle *et al.*, 2004; Robinson and Nickoloff, 2004). The digital follow-up of melanoma suspicious or equivocal lesions instead of their immediate excision has raised much concerns about the possibility of a delayed treatment of melanomas (Kittler and Binder, 2001; Carli *et al.*, 2003, 2004a; Argenziano, 2005). In contrast to such concerns, the DELM follow-up of atypical, but not melanoma suspicious or equivocal, lesions was shown to allow for the detection of early melanomas that have not yet acquired melanoma-typical ELM features (Haenssle *et al.*, 2004). Here, we demonstrate that a long-term follow-up of atypical melanocytic lesions by DELM increases the sensitivity for detection of cutaneous melanoma. We identified criteria for the selection of patients who would potentially benefit the most from the costly and time-consuming procedure of long-term sequential imaging of atypical melanocytic nevi.

¹Department of Dermatology, Georg-August-University Goettingen, Goettingen, Germany and ²Department of Genetic Epidemiology, Georg-August-University Goettingen, Goettingen, Germany

Correspondence: Dr Holger A. Haenssle, Department of Dermatology, Georg-August-University Goettingen, Von Siebold Strasse 3, D 37075 Goettingen, Germany. E-mail: h.haenssle@med.uni-goettingen.de

Abbreviations: AMS, atypical mole syndrome; DELM, digital epiluminescence microscopy; ELM, epiluminescence microscopy; FAMMM syndrome, familial atypical melanoma and multiple mole syndrome; MN, melanocytic nevi

Received 6 May 2005; revised 13 October 2005; accepted 21 October 2005

RESULTS

The melanoma risk correlates with the number of nevi and the attributed risk group

We found no association between the incidence of cutaneous melanoma during the study and sex, age, presence of ephelides, eye color, hair color, and skin type by univariate and multivariate statistical analyses. However, a significant association ($P \leq 0.012$) was found between the risk for melanoma during the study and the number of nevi at the first visit, the prospectively attributed risk group (I-III), and the presence of a personal and/or family melanoma history (Table 1).

First-visit examinations

At the first-visit examinations 237 pigmented lesions, including 37 melanomas, were excised. These 37 melanomas were identified either due to ELM criteria ($n=30$) or due to the assessment and the apprehension of the patients themselves ($n=7$, history of scaling, inflammation, enlargement, and change in color). Lesions excised due to the ELM algorithm of pattern analysis provided a higher chance of success than excisions performed due to the apprehension of the patient alone (Table 2).

DELM algorithm increases the sensitivity for melanoma detection during follow-up

The median number of DELM-documented lesions per patient visit was 13 (range 1–55) and a total of 7001

melanocytic skin lesions were followed by DELM. Overall, we identified 53 melanomas (25 invasive and 28 *in situ* melanomas) with a mean Breslow thickness of 0.43 mm for invasive melanomas (range 0.12–0.9 mm) during follow-up. In order to detect the 53 melanomas, a total of 637 excisions had to be performed. This corresponds to an overall chance of success during follow-up of 8.3% (Table 2). None of these melanomas was excised due to crude changes notable in comparison with conventional overview images.

Six of the 53 melanomas were detected by carefully taking the lesional history and by the apprehension of the patient himself without any other of the described examination procedures scoring suspicion (two invasive and four *in situ* melanomas). This examination technique resulted in one melanoma in 14 excisions (7.1% chance of success; Table 2).

In all, 13 melanomas developed *de novo* on uninvolved skin (according to comparison with baseline photographs) and were identified by ELM criteria (five invasive and eight *in situ* melanomas). The applied ELM algorithm yielded one melanoma in nine excisions (11.8% chance of success; Table 2).

During follow-up, 349 of the 637 removed lesions (5.0% of all 7001 DELM-documented lesions) were excised because of morphologic changes that had been identified by comparison of current with baseline DELM images showing only subtle phenotypic changes, which did not trigger

Table 1. Frequency of melanoma patients in defined patient subgroups as detected during the study

Patients subgroup characteristics	Number of patients with ≥ 1 melanoma	Odds ratio ¹	95% CI	P-values ²
<i>Number of nevi (estimated)</i>				
<50 nevi ($n=225$)	13	Reference	Reference	Reference
50–100 nevi ($n=214$)	33	2.97	[1.52–5.82]	0.0015*
> 100 nevi ($n=91$)	15	3.22	[1.46–7.08]	0.0036*
<i>Assignment of risk group</i>				
Group I – MN syndrome ($n=353$)	14	Reference	Reference	Reference
Group II – AM syndrome ($n=171$)	43	8.13	[4.31–15.37]	<0.001*
Group III – FAMMM syndrome ($n=6$) (all with history ³ of melanoma)	4	48.43	[8.17–287]	<0.001* ⁴
<i>Presence of melanoma history</i>				
Group I and no history ³ of melanoma ($n=261$)	5	Reference	Reference	Reference
Group I and history ³ of melanoma ($n=92$)	9	4.05	[1.37–12]	0.012*
Group II and no history ³ of melanoma ($n=74$)	7	Reference	Reference	Reference
Group II and history ³ of melanoma ($n=97$)	36	5.65	[2.34–13.63]	<0.001*

Group I: MN-syndrome group, patients with multiple (>50) common melanocytic nevi; Group II: AM-syndrome group, patients with atypical mole syndrome; Group III: FAMMM syndrome group, patients with familial atypical mole and multiple melanoma syndrome.

¹Odds ratios were modelled by logistic regression.

²P-values were calculated according to Wald- χ^2 statistic.

³History, includes personal melanoma history and/or family melanoma history.

⁴Due to the small n for the FAMMM syndrome group, Fishers exact test was used to calculate the P-value. All calculations were performed with SDS-software version 8.02.

*Statistically significant.

Table 2. Chance of success for the detection of cutaneous melanoma at first visits and follow-up examinations according to the different examination techniques

Technique of examination	Excisions performed to identify one melanoma (percentage of melanomas among excised lesions, absolute numbers)	
	At first visit	During follow-up
Patient apprehension alone	12 Excisions (8.3%, 84 excisions, 7 melanomas)	14 Excisions (7.1%, 84 excisions, 6 melanomas)
ELM criteria alone	5 Excisions (19.6%, 153 excisions, 30 melanomas)	9 Excisions (11.8%, 110 excisions, 13 melanomas)
DELM criteria alone	Not available at first visit	19 Excisions (5.2%, 349 excisions, 18 melanomas)
ELM plus DELM criteria	Not available at first visit	6 Excisions (17.0%, 94 excisions, 16 melanomas)
OVERALL	6 Excisions (15.6%, 237 excisions, 37 melanomas)	12 Excisions (8.3%, 637 excisions, 53 melanomas)

Patient apprehension alone: excisions performed due to patient apprehension without melanoma suspicion by other examination techniques.

ELM criteria alone: excisions performed due to suspicion by epiluminescence microscopy pattern analysis.

DELM criteria alone: excisions performed due to changes documented by digital epiluminescence microscopy without melanoma suspicion by other examination techniques.

ELM plus DELM criteria: excisions due to suspicion by epiluminescence microscopy plus additional documented changes by digital epiluminescence microscopy.

a suspicion for melanoma by the ELM algorithm (e.g. symmetrical or asymmetrical enlargement, progressing focal hyper- or hypopigmentation). Histopathological analysis of the 349 lesions revealed 18 (5.2%) early melanomas (nine invasive and nine *in situ* melanomas). Thus, the defined DELM criteria led to the identification of additional melanomas that would have been missed at this stage by the other examination techniques. This indicates that DELM increased the sensitivity of melanoma detection during follow-up. However, basing the decision for surgical intervention exclusively on DELM-documented changes during follow-up triggered the excision of 331 non-melanomas, which decreased the specificity of melanoma detection. The chance of success for melanoma detection by DELM analysis alone was one melanoma in 19 excisions (5.2% chance of success; Table 2).

In all, 16 melanomas showed DELM changes in addition to a suspicion for melanoma by ELM criteria (nine invasive and seven *in situ* melanomas). Lesions excised due to the presence of ELM plus DELM criteria scored the highest chance of success for melanoma detection during follow-up, with one melanoma detected in six excisions (17% chance of success; Table 2). This indicates that DELM might increase the specificity of melanoma detection, provided that it is used as a method additional to the ELM analysis.

Melanomas detected by DELM follow-up have the lowest Breslow tumor thickness

The tumor thickness according to Breslow is an important prognostic factor in primary cutaneous melanomas being associated with a linear increase in the risk of death (Breslow, 1980). We found that melanomas detected by DELM during follow-up had the lowest mean Breslow thickness (0.31 mm) when compared to melanomas detected by other techniques during follow-up (Figure 1). Overall, there was a thinner Breslow tumor thickness and thus potentially a better prognosis whenever the DELM technique was involved in melanoma detection during follow-up ($P=0.591$, Kruskal–Wallis test; Figure 1).

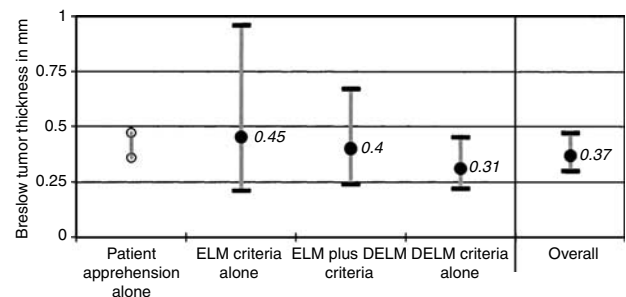


Figure 1. Mean and 95% confidence interval of the Breslow tumor thickness for melanomas detected during follow-up by the different indicated examination techniques ($P=0.591$; Kruskal–Wallis test). The measures depicted in this graph were log-transformed (in contrast to the “in text” measures). Two invasive melanomas were detected by the patients’ apprehension, without a suspicion by the other examination techniques (observed values shown); five invasive melanomas were detected by ELM criteria alone; nine invasive melanomas were detected by ELM criteria and also showed changes over time documented by DELM; nine invasive melanomas were exclusively detected by the comparison of DELM images with baseline images (DELM criteria alone).

High-risk patients benefit the most from DELM follow-up

In order to answer the question as to which of the defined risk groups benefit the most from long-term DELM follow-up, we calculated the percentage of melanomas detected exclusively by DELM changes in relation to all melanomas detected during follow-up for the risk groups I–III. During follow-up, the DELM criteria alone enabled the detection of 66.7% of melanomas (four out of six) in the group of familial atypical melanoma and multiple mole (FAMMM) patients (Group III; $n=6$), 32.5% of melanomas (13 out of 40) in the atypical mole syndrome (AMS) group of patients (Group II; $n=171$), but only 14.3% (1 out of 7) in the group of patients with multiple MN (Group I; $n=353$). Thus, a trend for a higher contribution of DELM follow-up to melanoma detection was documented in high-risk group III patients when compared to low-risk group I patients ($P=0.059$, Fisher’s exact test, exact logistic model).

DISCUSSION

Cutaneous melanoma and risk factors

In accordance with the known independent major risk indicators for cutaneous melanoma (Tucker *et al.*, 1997; Greene, 1999), we developed a special surveillance program that is restricted to a high-risk patient population. This program combines risk group stratification, patient apprehension, total body overview imaging, naked eye, ELM, and DELM examinations. The calculated odds ratios for melanoma development significantly correlated with the estimated total nevus count, the prospectively attributed risk group (I-III), and the presence of a personal and/or family melanoma history (Table 1), and therefore confirmed the value of the proposed stratification criteria.

Efficacy of long-term DELM follow-up of nevi

Since the first report in 1998 (Braun *et al.*, 1998), only a few clinical DELM follow-up studies of melanocytic skin lesions have been reported with heterogeneous results.

In a recent long-term DELM follow-up study, Schiffner *et al.* (2003) followed 272 MN without signs of dermoscopic atypia in 145 patients (75% low-risk patients, 25% high-risk patients), with a median duration of 24 months, and detected no melanomas. No melanomas were also detected by Braun *et al.* (1998), who followed patients with multiple common nevi using DELM for 2 years. Obviously, the use of a long-term follow-up DELM examination does not seem beneficial for melanoma detection when low-risk lesions (without signs of atypia) in mainly low-risk patients are monitored. Robinson and Nickoloff (2004) chose a setting for a long-term follow-up study (median follow-up of 36.2 months) in 100 high-risk patients similar to our own study. During annual follow-up visits, 193 (5.5%) of the 3482 digitally documented lesions were excised, with four lesions being melanoma *in situ*. During the follow-up period of our study (median: 32.2 months), the analysis of sequentially stored DELM images of atypical melanocytic lesions ($n=7001$) in patients with an increased risk for melanoma ($n=530$) identified 18 melanomas out of 349 DELM-based excised lesions. This corresponds to 34% of all melanomas detected during follow-up (18 out of 53). These melanomas were missed by the ELM examination that was systematically performed before the comparison of digitalized images with baseline images. Therefore, the DELM technique increased the sensitivity of melanoma detection. The question whether, and at what tumor thickness, these melanomas would have developed ELM features allowing their detection by conventional dermoscopy cannot be answered.

We also retrospectively calculated the chance of success (mostly representing the positive predictive value) for melanoma detection, which implies the number of lesions that had to be excised in order to detect one melanoma (Table 2). As expected, a high number of benign lesions were excised due to our cautious DELM criteria, causing a 5.2% chance of success. However, by adding the DELM analysis to the conventional ELM inspection, the chance of success for melanoma detection during follow-up was increased from 11.8% (110 excisions to detect 13 melanomas by ELM) to

17.0% (94 excisions to detect 16 melanomas by ELM suspicion plus DELM changes). This reduced the number of lesions that had to be excised in order to identify one melanoma from nine to six suspicious lesions (Table 2).

The observed increase in sensitivity and the improved chance of success for melanoma detection by additionally using DELM agree with the data of Kittler and Binder (2001), who evaluated the utility of sequential imaging of melanocytic skin lesions by using a set of 80 digital test images (including 10 early melanomas). Images were presented to 24 dermatologists. After presentation of follow-up images, the diagnostic accuracy improved significantly.

Pitfalls and drawbacks of DELM follow-up

DELM follow-up of atypical nevi is a time consuming procedure. The median number of DELM-followed lesions per patient was 13. While the conventional examination of an average study patient could be performed in 20 minutes, the addition of DELM extended the examination to 30, and in some cases even to 60 minutes (FAMMM group, >100 nevi). Less time might be required in routine practice as the study design demanded a consecutive clinical, ELM, and DELM examination, with many lesions being evaluated multiple times.

Our preliminary and cautious algorithm of DELM criteria for excisional biopsies caused a major percentage of non-melanoma excisions during follow-up (331 of 584, 56.6%). One of the major challenges in future will be to refine this algorithm to increase the specificity without losing sensitivity. The mere symmetrical increase in size of a lesion, for example, was a poor marker for identifying melanomas and contributed to most of our false-positive excisions. However, the ratio of one melanoma in 19 excised pigmented lesions yielded by the DELM algorithm alone still reaches a reasonable specificity in comparison to the reported ratios for expert dermoscopy users that ranged between 18 and 4.3 excised pigmented lesions in order to detect one melanoma over 5 years of observation (Carli *et al.*, 2004b).

The digital follow-up of equivocal or melanoma suspicious lesions instead of an immediate excision represents one of the most dangerous pitfalls of DELM. By such an approach, the sensitivity for melanoma detection at the first visit is reduced (Kittler and Binder, 2001). The only randomized controlled clinical trial assessing the impact of DELM follow-up failed to prove an increased sensitivity for melanoma detection, but noticed the occurrence of initial melanomas left unexcised until the second consultation, because the study design offered clinicians the digital follow-up of equivocal lesions (Carli *et al.*, 2004a). Moreover, patients may not be compliant and may therefore not attend follow-up appointments. As the "treatment threshold" should not be increased by the availability of DELM (Carli *et al.*, 2003; Argenziano, 2005), we did not submit equivocal or melanoma suspicious lesions to digital follow-up. Only atypical but melanoma unsuspecting lesions were DELM documented during our study, which offered the potential to detect additional melanomas among otherwise (by clinical and ELM analysis) unsuspecting lesions.

Use of DELM may improve melanoma prognosis

The Breslow thickness is one of the most important prognostic factors in primary cutaneous melanomas, with an increasing tumor thickness being associated with a linear increase in the risk of death. We found a thinner Breslow tumor thickness (Figure 1) and thus a possible better prognosis whenever the DELM technique was involved in melanoma detection during follow-up ($P=0.591$, Kruskal–Wallis test).

High-risk patients benefit the most from long-term DELM follow-up

Patients with FAMMM syndrome and AMS seem to benefit the most from DELM follow-up because in these groups 66.7 and 32.5% of all melanomas were identified exclusively based on comparative analysis of DELM images, respectively. In contrast, only 14.3% of melanomas in the group of patients with multiple common MN were identified with DELM alone. Assuming that the time for progression to cutaneous melanoma is similar in the different risk groups, one reason for this finding could be that shorter intervals in follow-up for AMS and FAMMM syndrome patients help to identify melanomas by subtle DELM-documented changes before these lesions develop ELM-typical melanoma features. The earliest of the six melanomas detected by DELM in FAMMM patients was diagnosed after 1 year of follow-up, and all were excised at a low tumor thickness (two melanomas *in situ*, invasive melanomas from 0.25 to 0.9 mm tumor thickness), making an undue DELM follow-up of pre-existing melanomas for 1–1½ years very unlikely.

In conclusion, during this long-term follow-up program, DELM proved to be a valuable tool for the early detection of cutaneous melanomas in atypical melanocytic lesions primarily not suspicious for melanoma. The application of the DELM criteria increased the sensitivity of the conventional ELM analysis, especially for defined high-risk patient groups, including AMS and FAMMM syndrome patients. A lower Breslow tumor thickness was present whenever DELM was involved in the decision for an excisional biopsy. Limitations arising from the observational uncontrolled nature of this study require further randomized trials for confirmation of our results. Another objective for future studies should be the refinement of the DELM algorithm to reduce the number of unnecessary excisions, and thus to further increase the effectiveness of DELM for follow-up of patients at risk for melanoma.

MATERIALS AND METHODS

Patients' characteristics

All clinical investigation was conducted according to the Declaration of Helsinki Principles. Institutional approval and patient consent were obtained for all experimental interventions. The study included 530 patients (56.5% females, 43.5% males) with an increased risk for developing melanoma. Patients were prospectively stratified into three groups according to the presence of melanoma risk factors: Group I, patients with multiple (more than 50) MN or three or less clinical atypical nevi ($n=353$); Group II, patients with AMS (Tucker *et al.*, 1997) additionally characterized by three or more

histologically dysplastic nevi in their personal medical history ($n=171$); Group III, patients with familial atypical mole and multiple melanoma (FAMMM) syndrome characterized by a family history of at least two melanomas in relatives of the first or second degree ($n=6$). The first two risk groups were further subdivided according to a positive or negative personal and/or family history of melanoma. Patients' characteristics, including age, sex, hair color, eye color, skin type (I–IV, Fitzpatrick's classification), presence or absence of ephelides, and the estimated number of nevi, were prospectively entered into a database. In all, 36.8% of the patients had a personal and/or family history of melanoma, 32.3% belonged to the group of AMS patients, and 57.6% had more than 50 nevi. The mean age was 40 years (range 2–89 years) and the median surveillance time was 32.2 months (range 3–77 months).

Selected data of 212 patients after a median follow-up of 18 months were subjected to analysis and publication earlier (Haenssle *et al.*, 2004).

Patients' examination

Data of 530 patients were collected during 7 years (1997–2004). At the first visit the whole integument was examined by the unaided eye, the number of nevi was estimated (<50, 50–100, >100) and ELM examination of all clinically atypical nevi was performed using a portable device (Welch Allyn, Skaneateles Falls, NY). The ELM pattern analysis of pigmented skin lesions as described by Pehamberger *et al.* (1987) was used as a diagnostic algorithm for differentiating benign melanocytic lesions from melanoma. Melanocytic lesions suspicious of malignancy and equivocal lesions by this algorithm were immediately excised. Lesions presenting clinical criteria of atypia (asymmetry in shape, variegated color) or ELM criteria of atypia (irregular/prominent pigment network, irregular overall pigmentation) (Ascierto *et al.*, 2000) were marked on digital overview images and electronically stored by using two DELM-imaging systems (FotoFinder dermoscope, Teachsreen Software GmbH, Bad Birnbach, Germany or Hikoscope[®], Hiko, Pirmasens, Germany). Additional standardized conventional overview photographs facilitated the detection of newly arising lesions (Kelly *et al.*, 1997).

Follow-up examinations were scheduled for every 3, 6, or 12 months depending on the individual risk. Patients were asked about new or changing nevi, conventional overview photographs were compared with the corresponding body surface, and all clinically atypic nevi were examined by ELM. Newly developed lesions were treated as described for first-visit examinations. Nevi that had been digitally documented during a previous visit ($n=7001$) were again digitally stored by DELM and then compared side by side with the corresponding baseline image on a split screen.

Excisional biopsy after DELM analysis

Criteria leading to the excision of digitally stored lesions were symmetrical or asymmetrical enlargement, changes in shape or color, new signs of regression, or changes in the ELM structure (Binder *et al.*, 1998; Kittler *et al.*, 2000). Excision was performed when at least one of these criteria had developed in a lesion, even if the lesion itself was not regarded suspicious for malignancy by pattern analysis. In agreement with others, we did not excise lesions developing a darker or lighter overall pigmentation or lesions with

a decrease in the number of initially present black dots (Braun *et al.*, 1998; Kittler *et al.*, 2000).

Statistical evaluation

The statistical analysis was performed using SAS 8.6 software. The data were prospectively entered and stored in a Microsoft Access database. Plausibility, accuracy, and completeness were verified.

CONFLICT OF INTEREST

The authors state no conflict of interest. The corresponding author has full access to all the data in the study and had the final responsibility for the decision to submit the paper for publication.

ACKNOWLEDGMENTS

We thank the Cancer Society of Lower Saxony (Niedersaechsische Krebsgesellschaft, Hannover, Germany) for their financial support. The FotoFinder dermoscope is a donation of Teachscreen Software GmbH (Bad Birnbach, Germany) to the University Hospital Goettingen.

REFERENCES

Argenziano G (2005) The impact of dermoscopy on the management of pigmented skin lesions: the role of follow-up. *J Am Acad Dermatol* 52:178-80

Ascierto PA, Palmieri G, Celentano E, Parasole R, Caraco C, Daponte A *et al.* (2000) Sensitivity and specificity of epiluminescence microscopy: evaluation on a sample of 2731 excised cutaneous pigmented lesions. The Melanoma Cooperative Study. *Br J Dermatol* 142:893-8

Binder M, Kittler H, Seeber A, Steiner A, Pehamberger H, Wolff K (1998) Epiluminescence microscopy-based classification of pigmented skin lesions using computerized image analysis and an artificial neural network. *Melanoma Res* 8:261-6

Braun RP, Lemonnier E, Guilloid J, Skaria A, Salomon D, Saurat JH (1998) Two types of pattern modification detected on the follow-up of benign melanocytic skin lesions by digitized epiluminescence microscopy. *Melanoma Res* 8:431-7

Breslow A (1980) Prognosis in cutaneous melanoma: tumor thickness as a guide to treatment. *Pathol Annu* 15:1-22

Carli P, de Giorgi V, Chiarugi A, Nardini P, Weinstock MA, Crocetti E *et al.* (2004a) Addition of dermoscopy to conventional naked-eye examination

in melanoma screening: a randomized study. *J Am Acad Dermatol* 50:683-9

Carli P, de Giorgi V, Crocetti E, Mannone F, Massi D, Chiarugi A *et al.* (2004b) Improvement of malignant/benign ratio in excised melanocytic lesions in the "dermoscopy era": a retrospective study 1997-2001. *Br J Dermatol* 150:687-92

Carli P, de Giorgi V, Giannotti B (2003) Why digital follow-up of dermoscopically equivocal pigmented lesions should be discouraged. *Br J Dermatol* 148:1272-3

Carli P, Massi D, de Giorgi V, Giannotti B (2002) Clinically and dermoscopically featureless melanoma: when prevention fails. *J Am Acad Dermatol* 46:957-9

Greene MH (1999) The genetics of hereditary melanoma and nevi. 1998 update. *Cancer* 86:2464-77

Haenssle HA, Vente C, Bertsch HP, Rupprecht R, Abuzahra F, Junghans V *et al.* (2004) Results of a surveillance programme for patients at high risk of malignant melanoma using digital and conventional dermoscopy. *Eur J Cancer Prev* 13:133-8

Kelly JW, Yeatman JM, Regalia C, Mason G, Henham AP (1997) A high incidence of melanoma found in patients with multiple dysplastic naevi by photographic surveillance. *Med J Aust* 167:191-4

Kittler H, Binder M (2001) Risks and benefits of sequential imaging of melanocytic skin lesions in patients with multiple atypical nevi. *Arch Dermatol* 137:1590-5

Kittler H, Pehamberger H, Wolff K, Binder M (2000) Follow-up of melanocytic skin lesions with digital epiluminescence microscopy: patterns of modifications observed in early melanoma, atypical nevi, and common nevi. *J Am Acad Dermatol* 43:467-76

Menzies SW, Gutenev A, Avramidis M, Batrac A, McCarthy WH (2001) Short-term digital surface microscopic monitoring of atypical or changing melanocytic lesions. *Arch Dermatol* 137:1583-9

Pehamberger H, Steiner A, Wolff K (1987) *In vivo* epiluminescence microscopy of pigmented skin lesions. I. Pattern analysis of pigmented skin lesions. *J Am Acad Dermatol* 17:571-83

Robinson JK, Nickoloff BJ (2004) Digital epiluminescence microscopy monitoring of high-risk patients. *Arch Dermatol* 140:49-56

Schiffner R, Schiffner-Rohe J, Landthaler M, Stolz W (2003) Long-term dermoscopic follow-up of melanocytic naevi: clinical outcome and patient compliance. *Br J Dermatol* 149:79-86

Tucker MA, Halpern A, Holly EA, Hartge P, Elder DE, Sagebiel RW *et al.* (1997) Clinically recognized dysplastic nevi. A central risk factor for cutaneous melanoma. *JAMA* 277:1439-44